

ANATOMI FUNGSIONAL

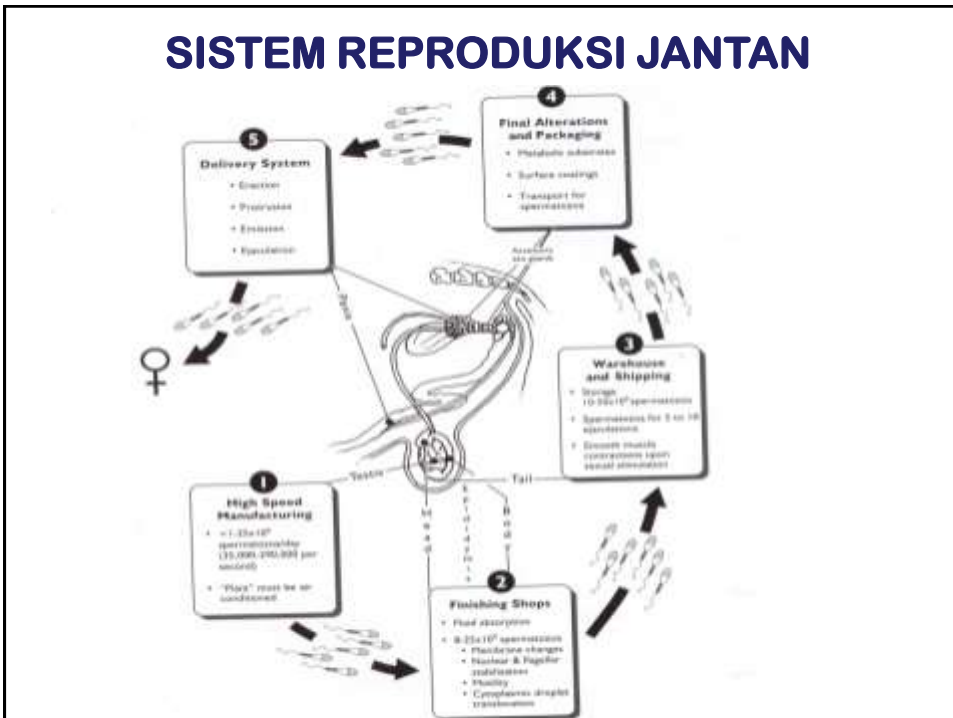ORGAN REPRODUKSI JANTAN

- Prof. Dr. Drh. Tutty L. Yusuf MS
- Drh. Mokhammad Fakhru Ulum, MSi, PhD

Divisi Reproduksi dan Kebidanan
Departemen Klinik Reproduksi dan Patologi
Fakultas Kedokteran Hewan
Institut Pertanian Bogor
2017

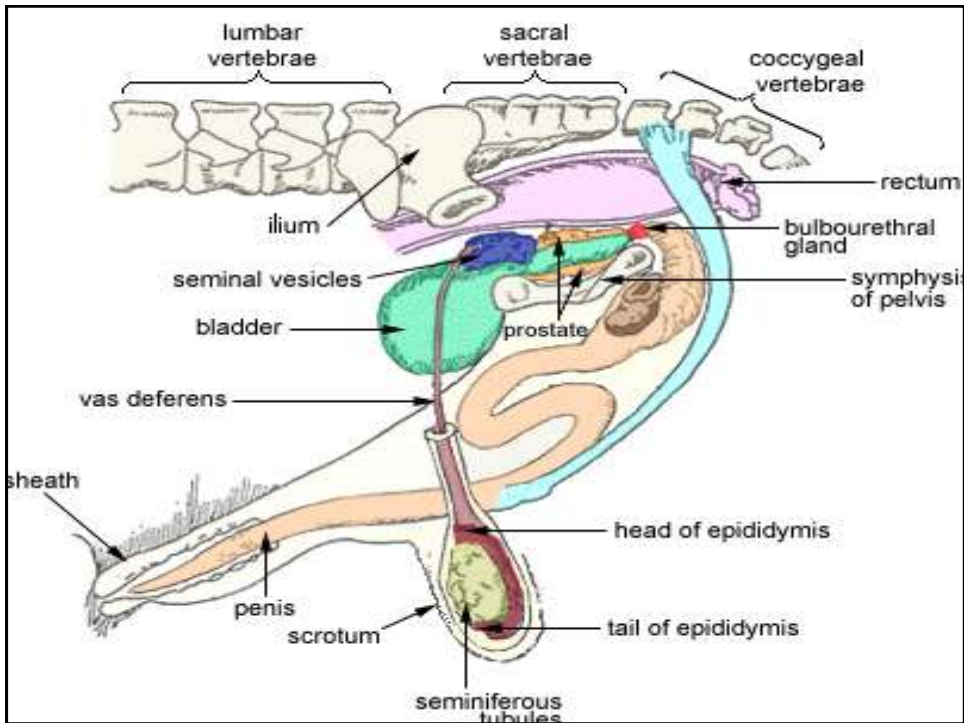
ANATOMI & FUNGSI ORGAN REPRODUKSI
FISIOLOGI SEMEN
STRUKTUR SPERMATOZOA
SPERMATOGENESIS
TRANSPOR SPERMA
KAPASITASI DAN REAKSI AKROSOM
KELAKUAN KELAMIN
TEKNIK KOLEKSI SEMEN
TEKNIK EVALUASI SEMEN

SISTEM REPRODUKSI JANTAN

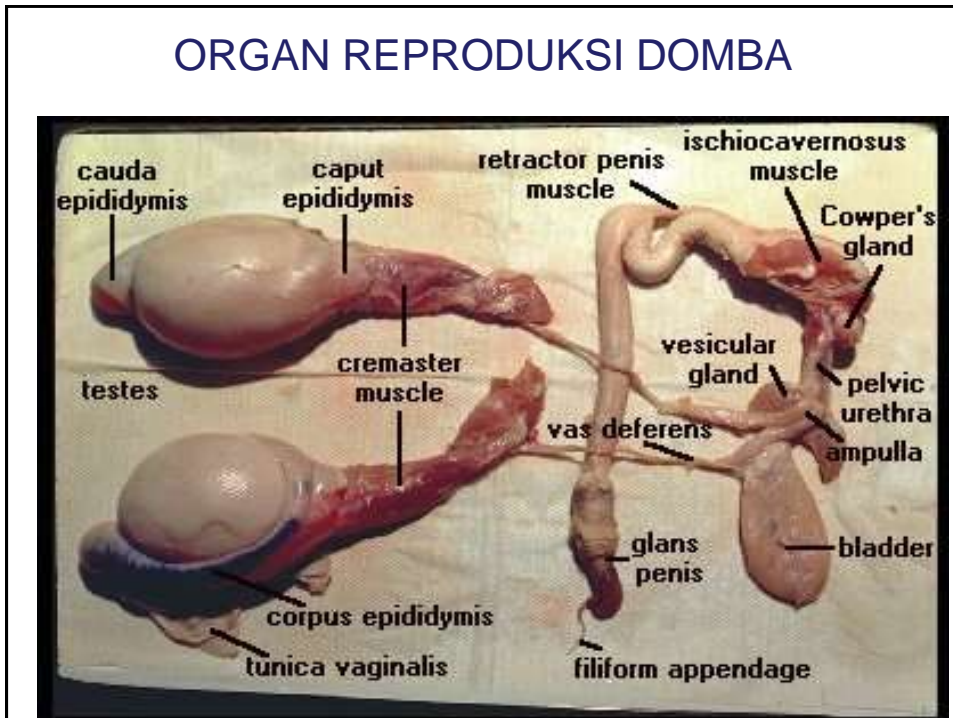


SISTEM REPRODUKSI JANTAN

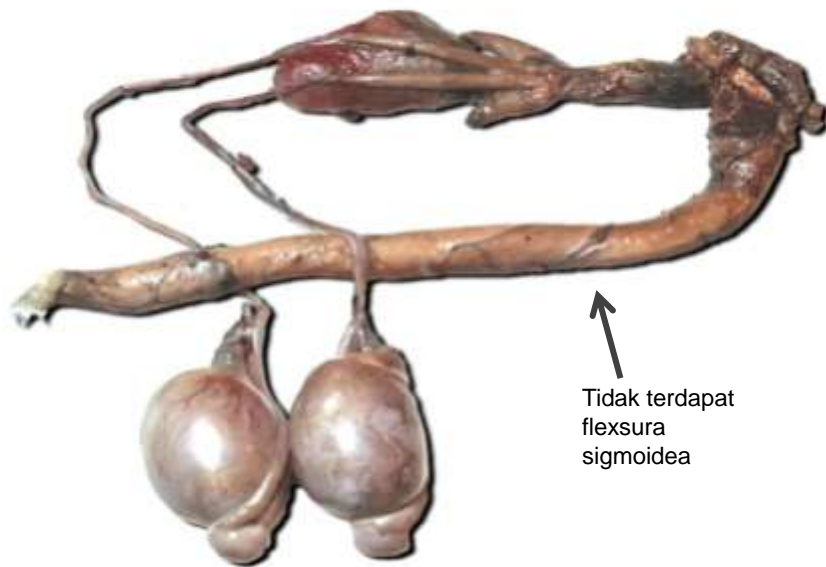
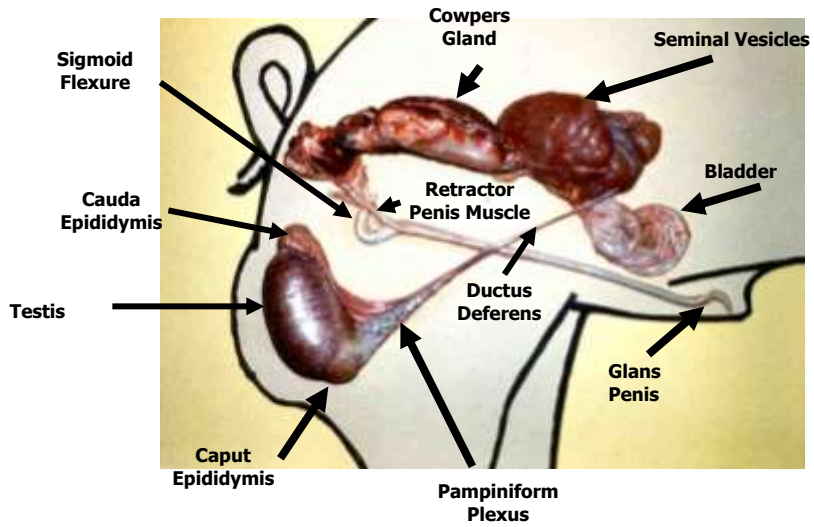
Gonad	: TESTIS
Saluran reproduksi	: EPIDIDYMIS Vas Deferens Uretra/Urogenitalis
Kelenjar Aksesorius	: Kelenjar Vesikularis Prostat Cowper
Organ Kopulatoris	: PENIS



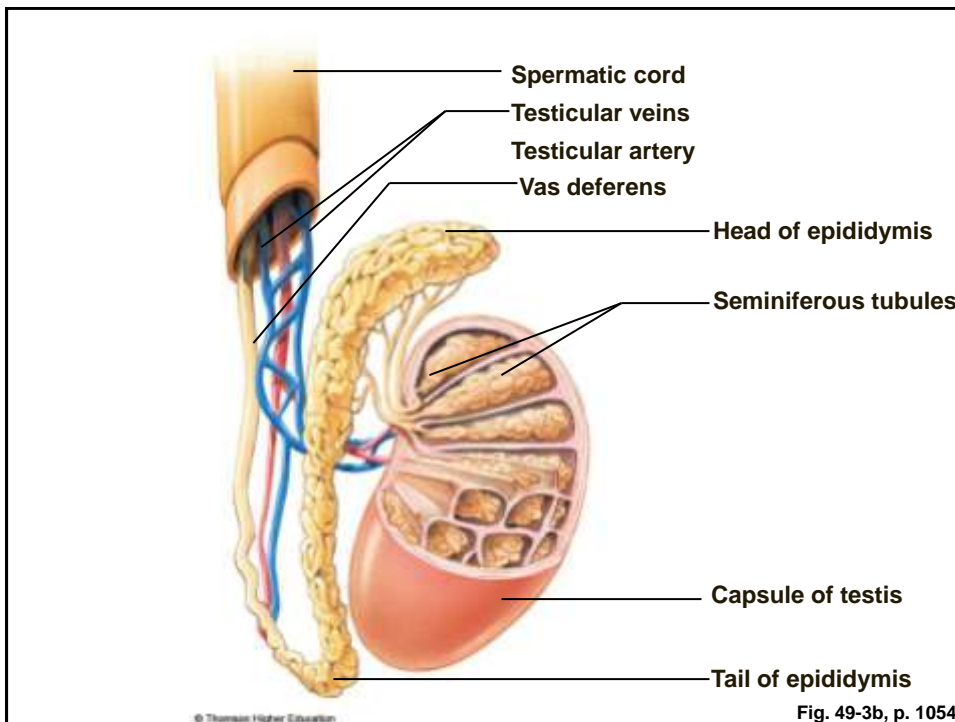
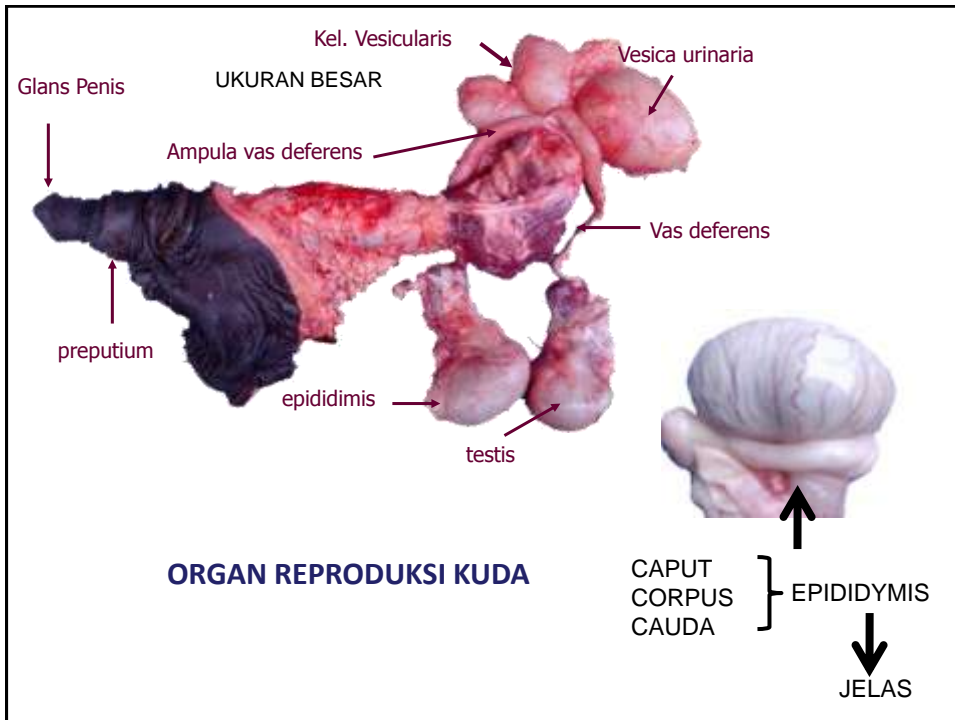
ORGAN REPRODUKSI DOMBA



ORGAN REPRODUKSI BABI JANTAN

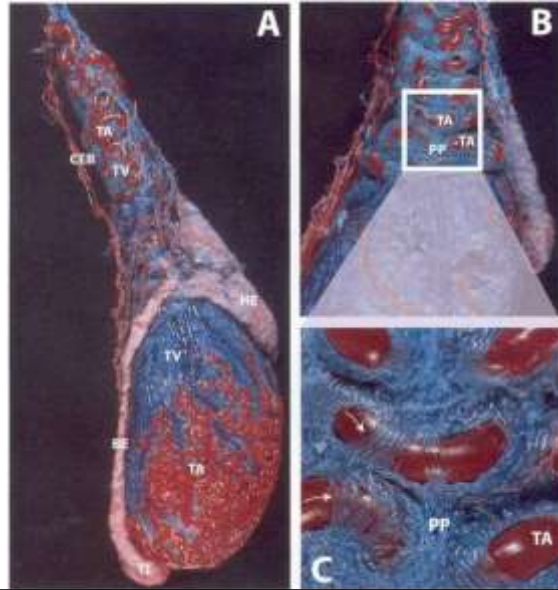


ORGAN REPRODUKSI RUSA



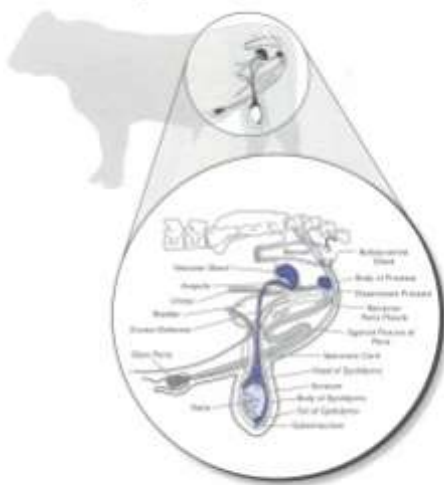Pampiniform Plexus

- Blood Supply to the Testes



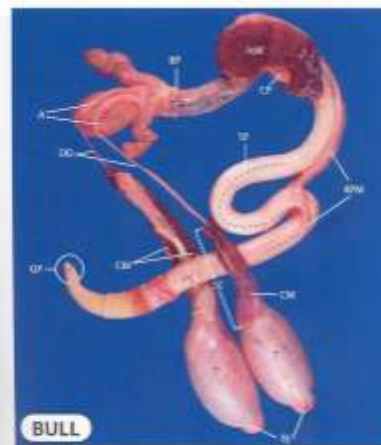
The Fibro-elastic Penis

Figure 3-4. Bull Reproductive Tract



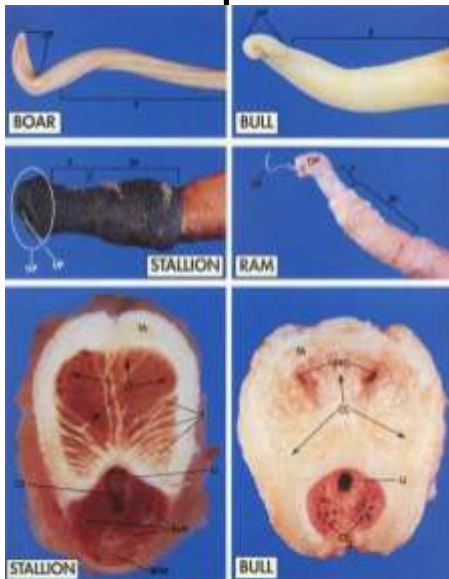
Schematic illustration of a sagittal view of the bull reproductive tract. Modified from Colquhoun and Stone, 1962. Reprinted, as permission, American Veterinary Medical Association, 1997. From: Dissection, Identification and Care, 3rd Edition, Philadelphia, W.B. Saunders Company, New York.

Figure 3-4. Eviscerated Bull Reproductive Tract



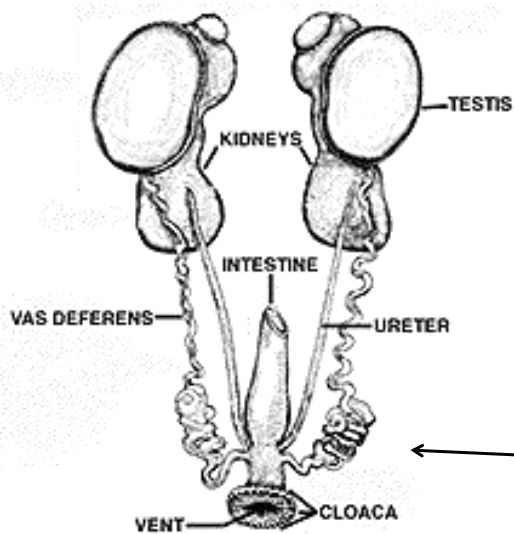
BULL
 A = Ampulla
 BP = Body of Prepuce
 CM = Cremaster Muscle
 CP = Cloaca/Penis
 DE = Ductus Deferens
 EP = Epididymus
 IMB = Ilioinguinal Muscle
 IPB = Iliopectineal Muscle
 IPPM = Retractor Penis Muscle
 SC = Spermatic Cord
 SP = Sigmoid Plexus
 T = Testis
 IMB = Ilioinguinal Muscle
 IPB = Iliopectineal Muscle
 IPPM = Retractor Penis Muscle
 SC = Spermatic Cord
 SP = Sigmoid Plexus
 T = Testis
 TC = Tail of Epididymus
 UB = Uterine Band
 UM = Uterine Muscle
 VG = Vesicular Gland

Comparative Penis Anatomy



- Fibro-elastic penes
 - Boars
 - Bulls
 - Rams
- Vascular-muscular penes
 - Stallions
 - Men

ORGAN REPRODUKSI UNGGAS



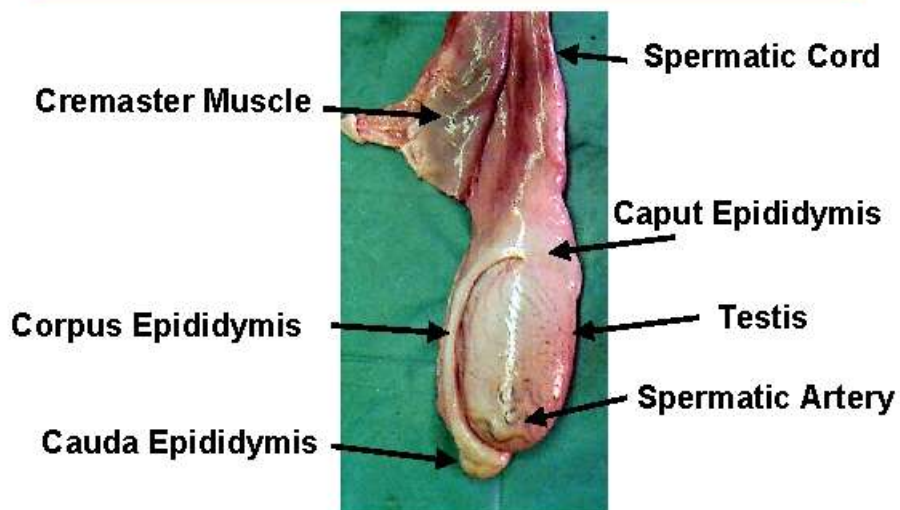
← **SPERMATHEKA**
(PENYIMPANAN SPERMATOZOA)

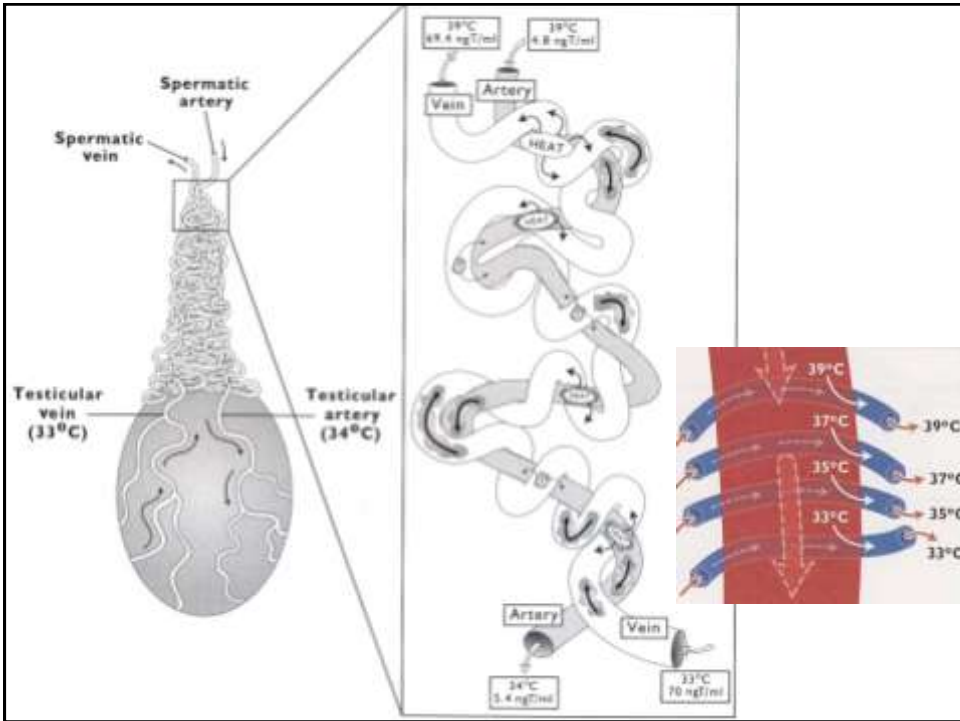
Male

SPERMATIC CORDS

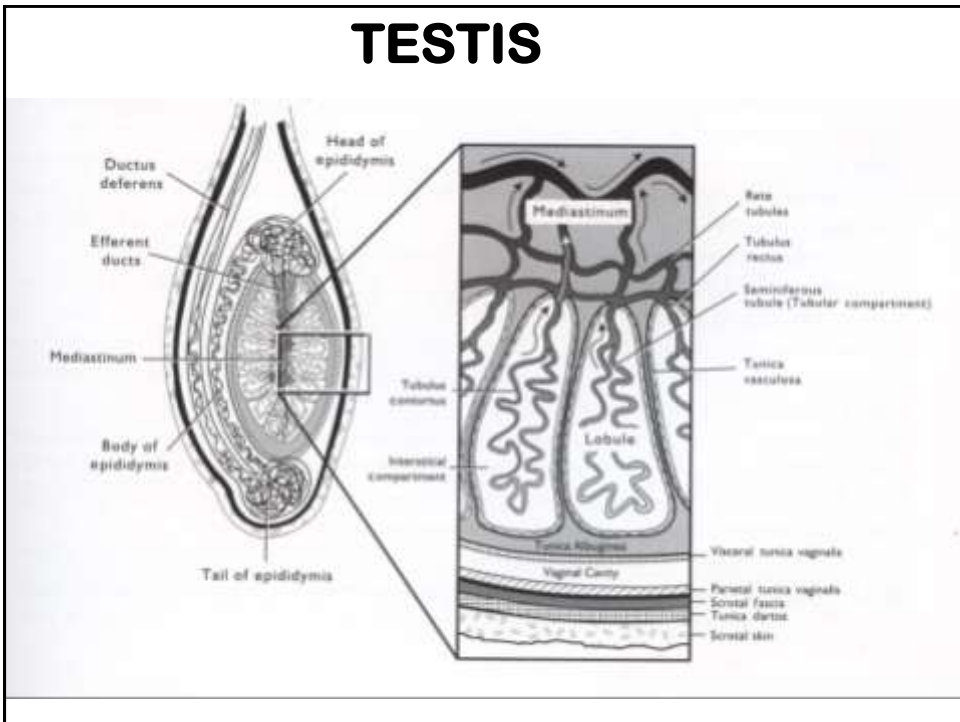
- ARTERI & VENA
SALURAN LIMFE, SYARAF
- PERTUKARAN TEMPERATUR
(PAMPINIFORMIS EXCHANGE)
- MUSKULUS CREMASTER :
THERMOREGULATORIS TESTIS
(CONTROL OF TESTICULAR TEMPERATURE)

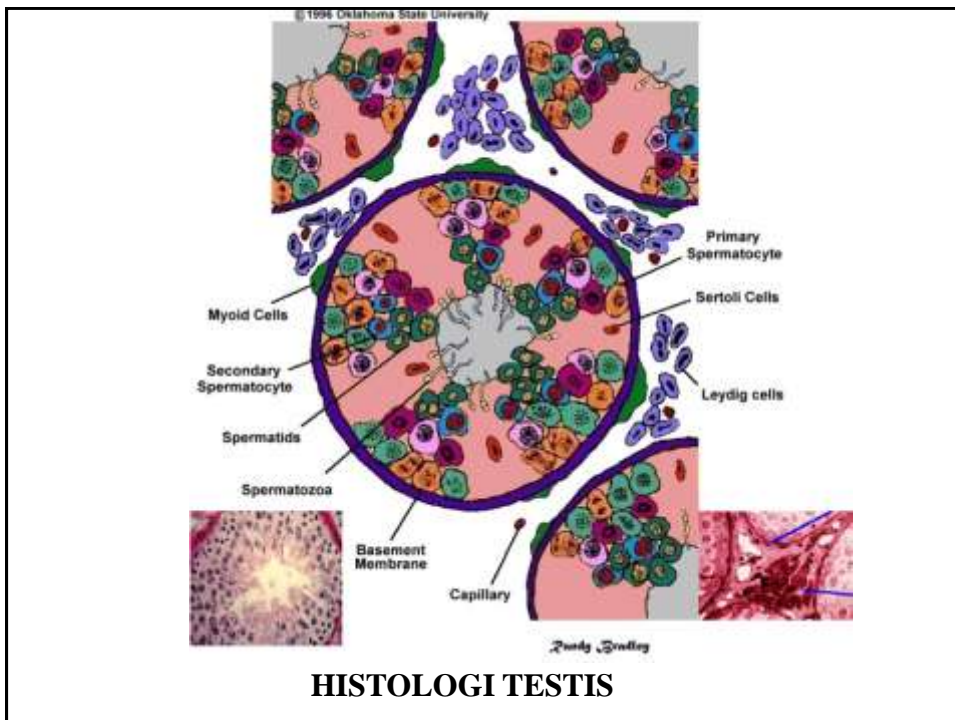
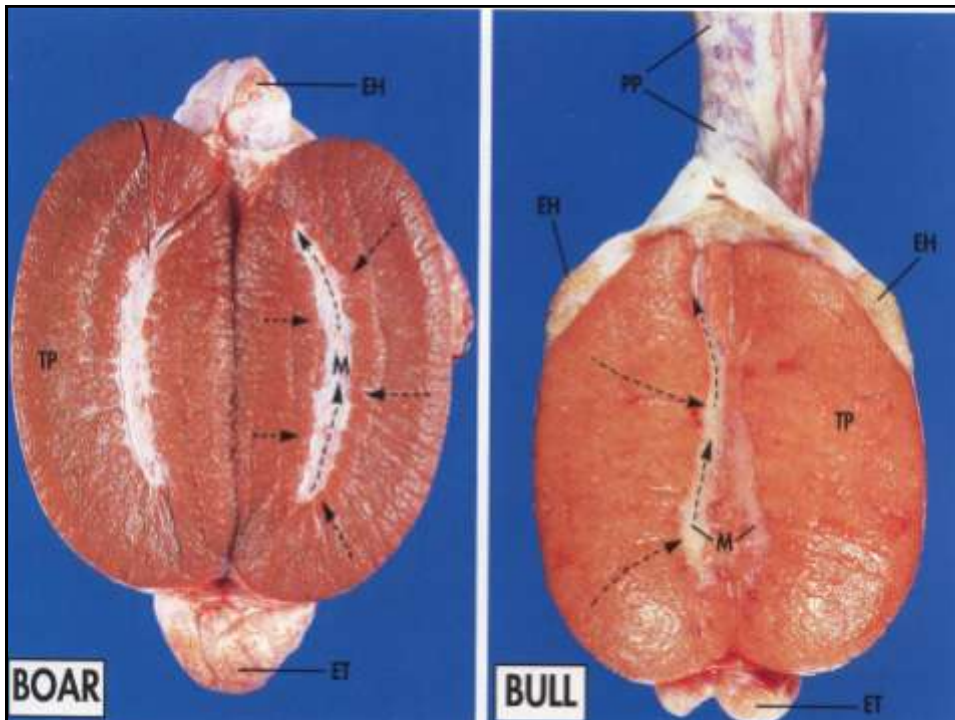
Testis & Spermatic Cord

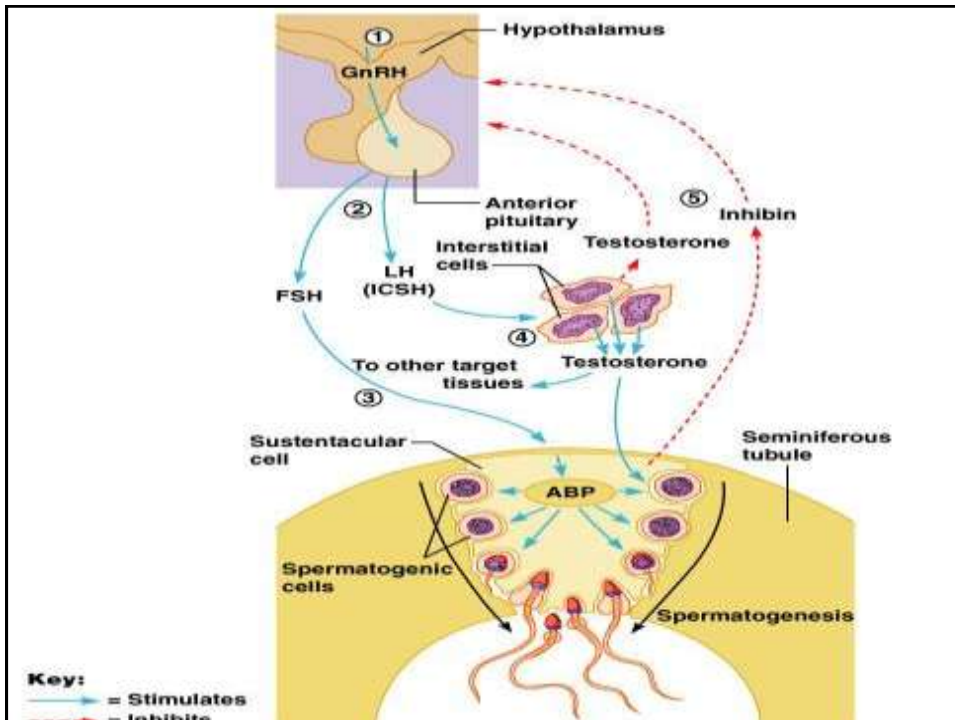




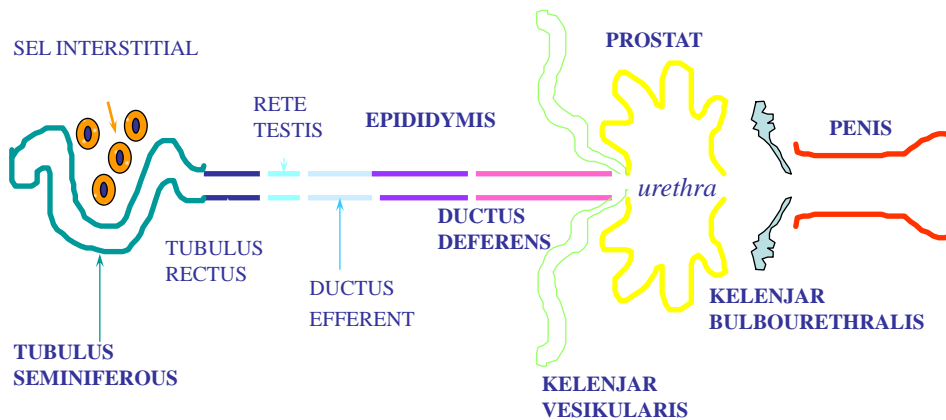
TESTIS

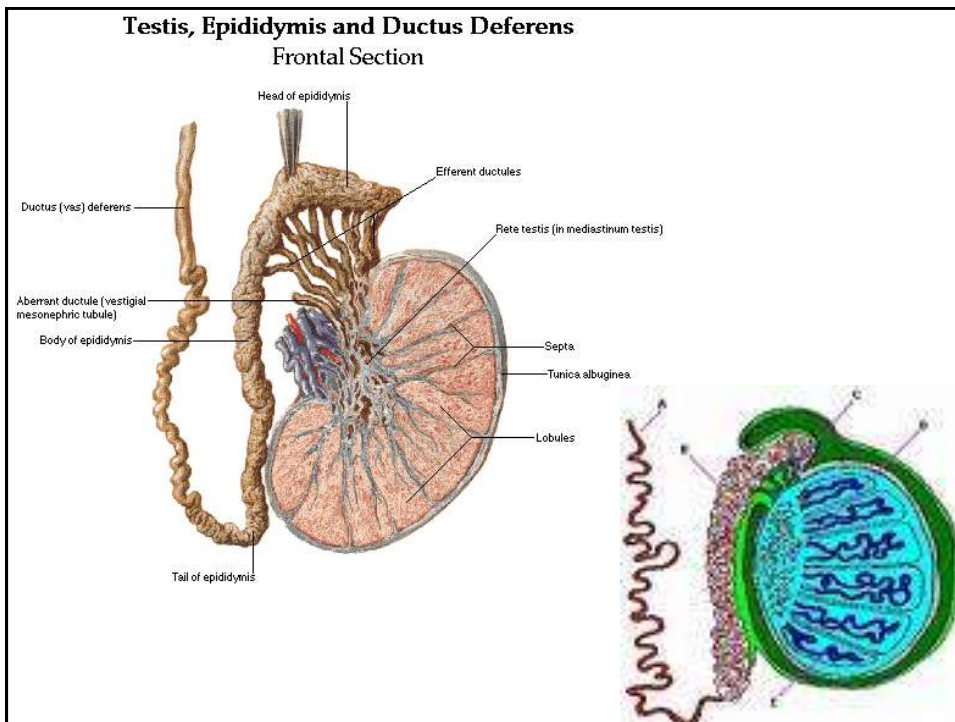
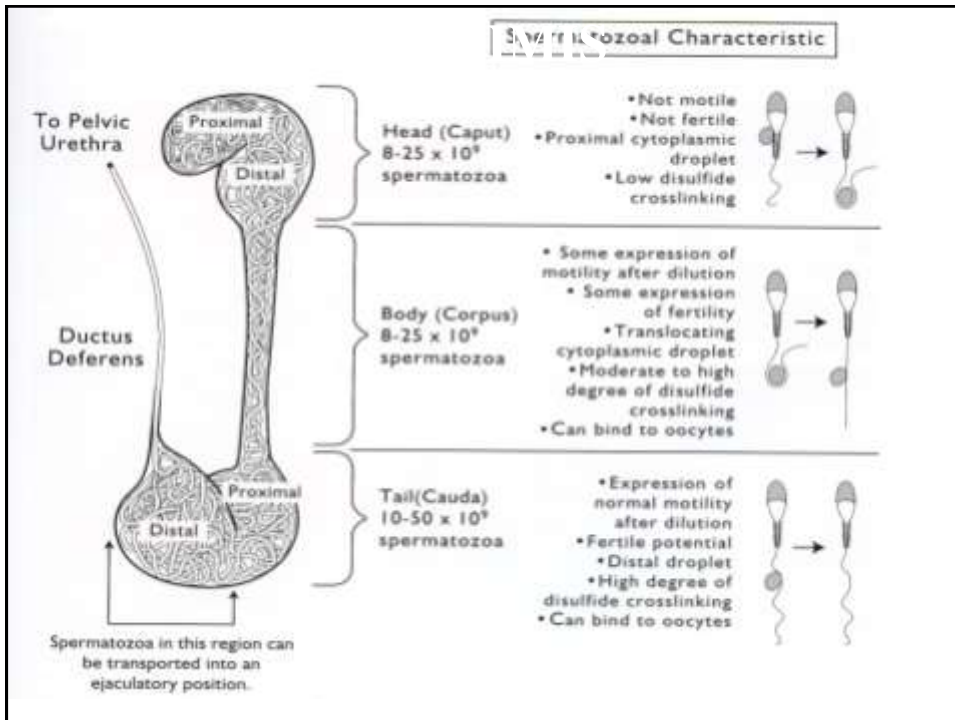






SALURAN REPRODUKSI JANTAN

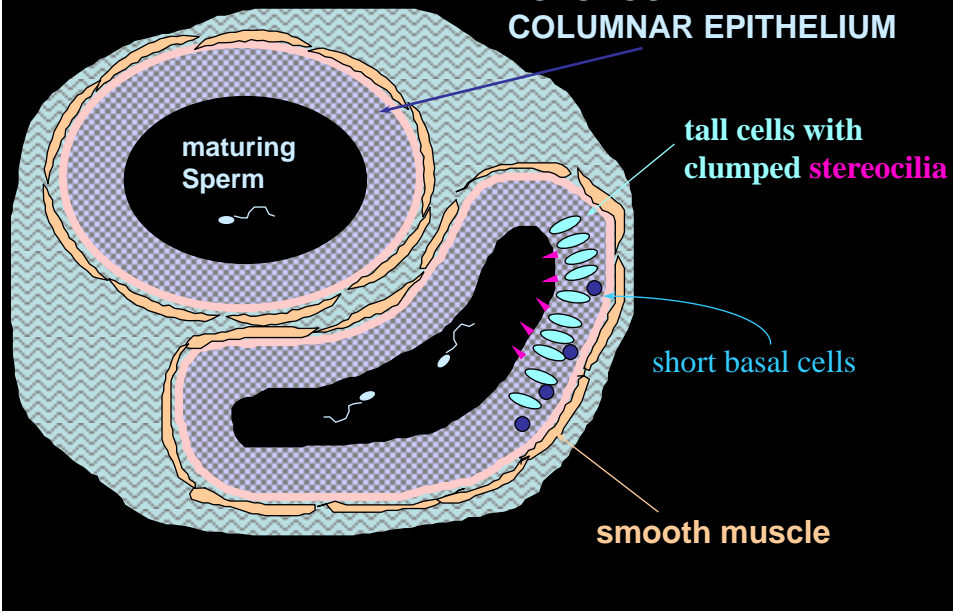




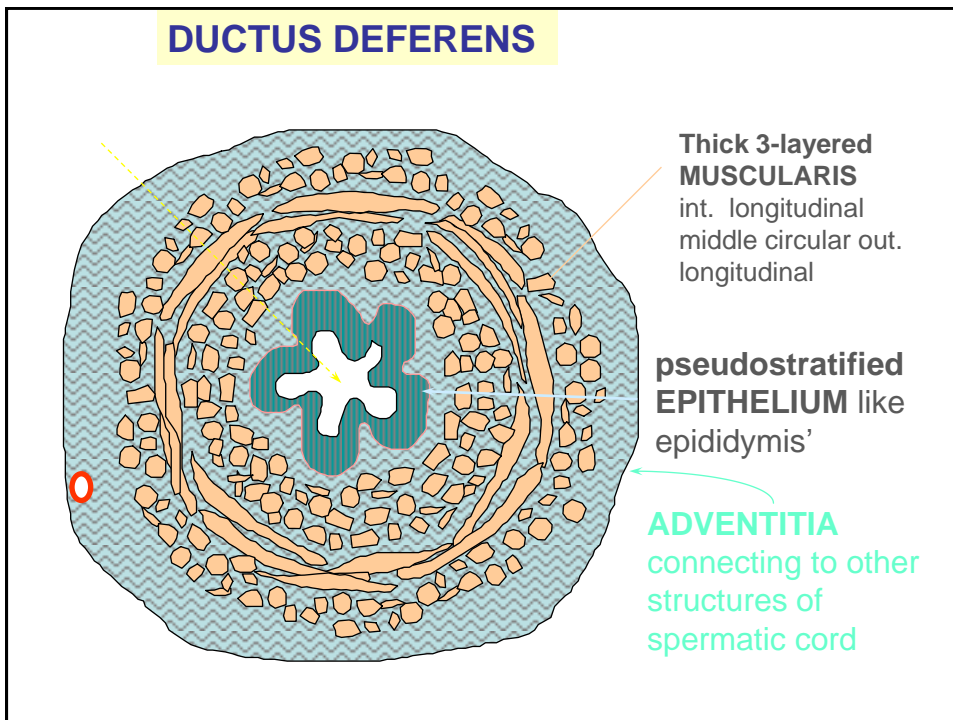
EPIDIDYMIS

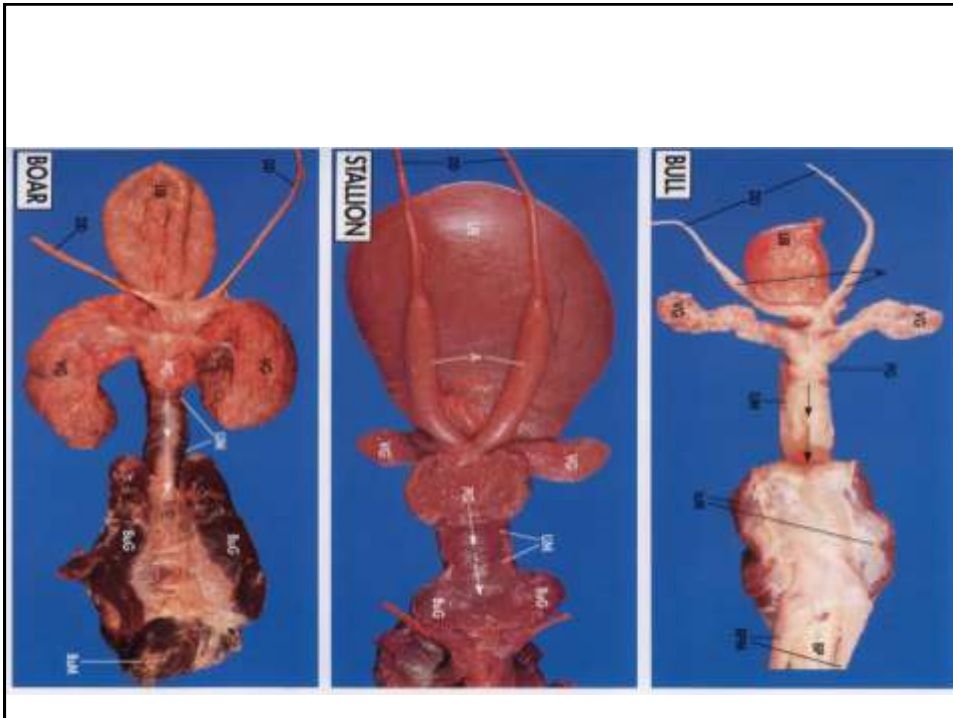
only one, but coiled = repeating profiles

PSEUDOSTRATIFIED COLUMNAR EPITHELIUM



DUCTUS DEFERENS





Kelenjar Vesikularis

Sekresi:

- (i) seminogelin
- (ii) fructose
- (iii) prostaglandins

Kelenjar Prostat

Secretes:

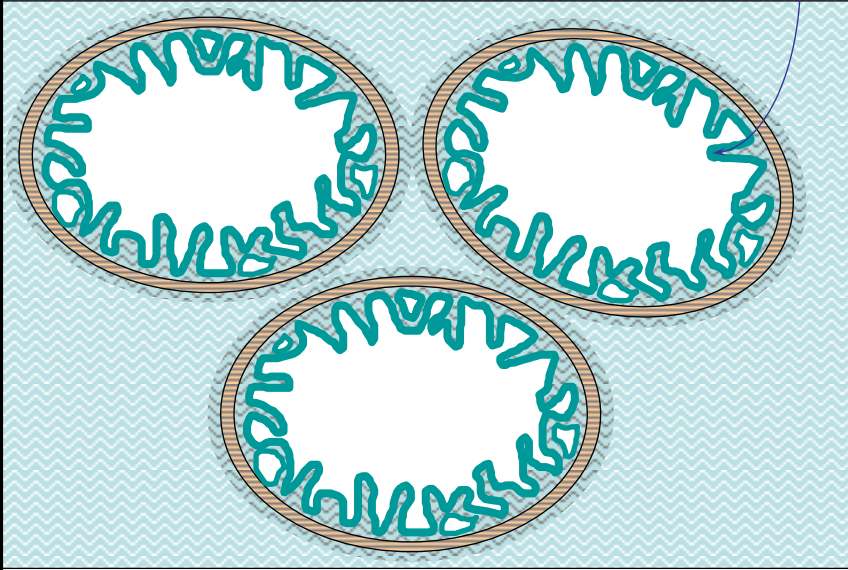
- (i) PSA protease
- (ii) acid phosphatase
- (iii) citric acid

Kelenjar Bulbouretralis

Secretes mucus for urethral lubrication

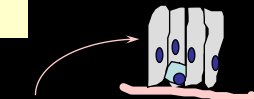
KELENJAR VESIKULARIS

Highly folded & outpouching T MUCOSA with irregular pale "simple" columnar epithelium

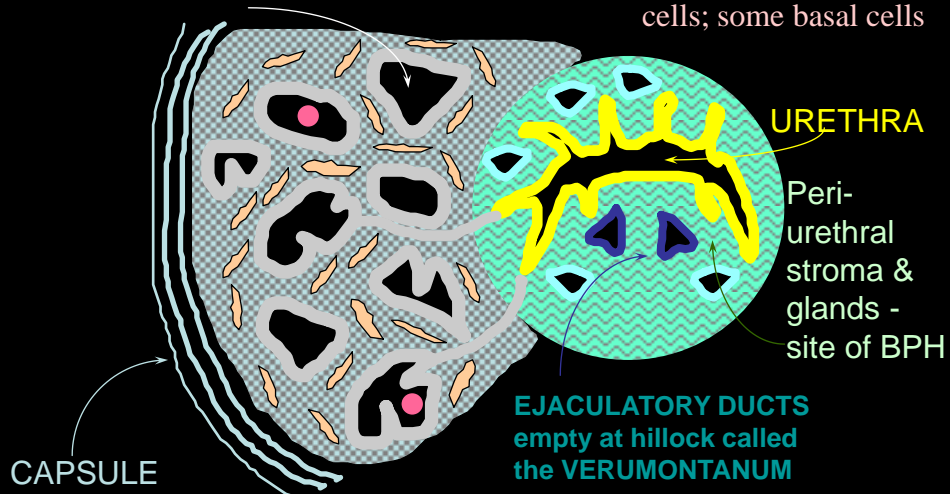


KELENJAR PROSTAT

Main ALVEOLI - irregular epithelial lining



tall, pale, non-mucous cells; some basal cells



URETHRA

Peri-urethral stroma & glands - site of BPH

EJACULATORY DUCTS empty at hillock called the VERUMONTANUM

CAPSULE

Capsule is important in restraining the spread of cancer

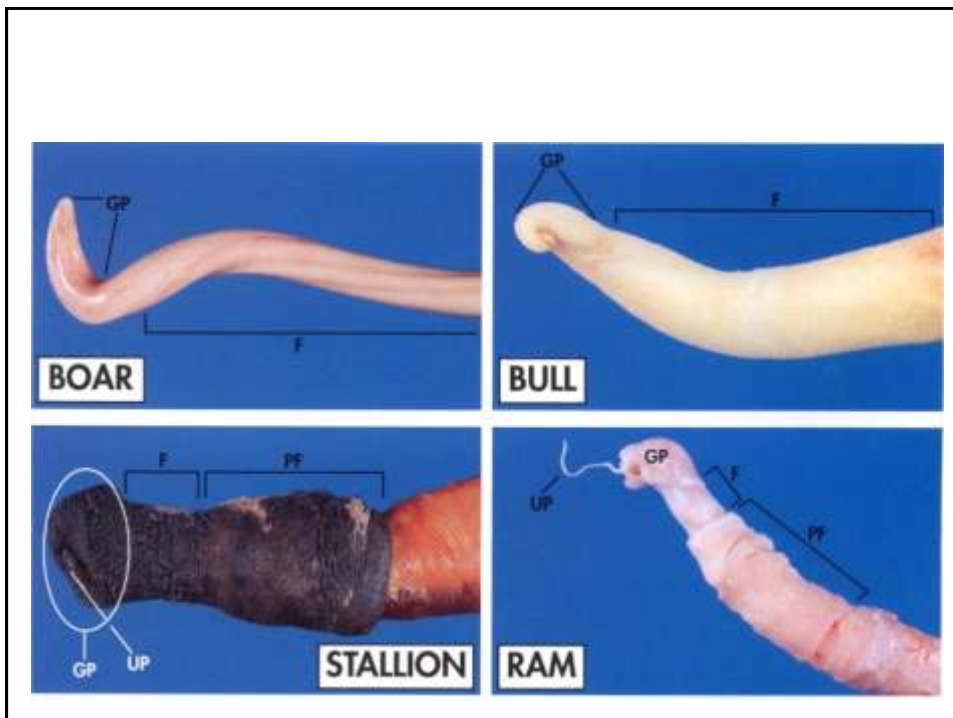
TIPE PENIS

CAVERNOSUS/MUSCULARIS

LEMAS KALAU TIDAK EREKSI
TIDAK MEMPUNYAI FLEKSURA SIGMOIDEA
TERDAPAT PADA CARNIVORA :
MACACA, KUDA, MANUSIA

FIBROELASTIK

MEMPUNYAI FLEKSURA SIGMOIDEA
TETAP KERAS MESKIPUN TIDAK EREKSI
PADA RUMINANSIA (KECUALI RUSA)
BABI



MEKANISME KERJA ORGAN REPRODUKSI JANTAN

